



American Academy of Oral
& Maxillofacial Pathology

Clinical Pathology Conference

Dr. Don Cohen
Moderator

These cases and the images associated with each case are copyrighted by the American Academy of Oral and Maxillofacial Pathology.

Permission is granted for use of the cases and images for educational purposes only. The rights to publication have been assigned by Academy of Oral and Maxillofacial Pathology to the individual contributors of the cases. Any use of the cases or the corresponding images for other than educational purposes is strictly forbidden.

Clinical Pathology Conference

Moderator: Donald M. Cohen

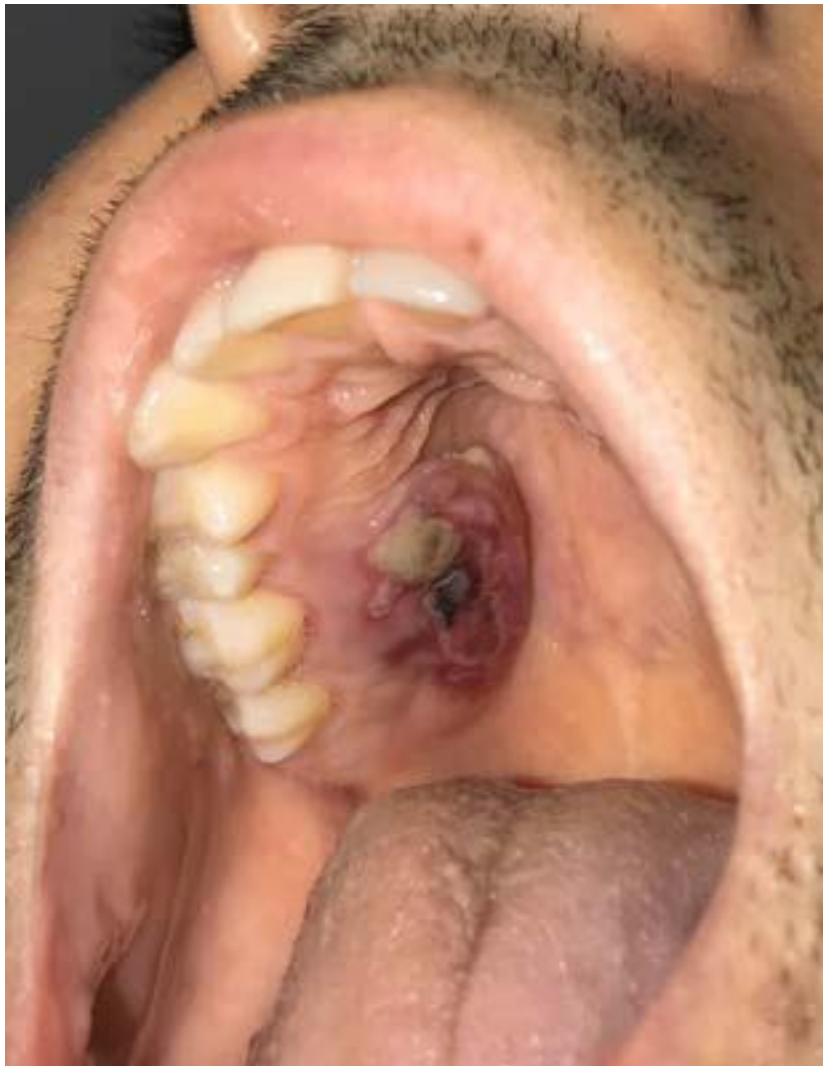	Discussant	Contributor	Page
Case #1	Dr. Neetha Santosh Indiana University School of Dentistry nsantosh@iu.edu	Dr. Nadim Islam University of Florida, College of Dentistry Mislam@dental.ufl.edu	
Case #2	Dr. Eugene Ko University of Pennsylvania School of Dental Medicine eugko@upenn.edu	Dr. Elizabeth Philipone Columbia University Medical Center	
Case #3	Dr. Jessica Wollenberg Randolph Oral Pathology Associates, LLC Wollenj1923@gmail.com	Dr. Rafik Abdelsayed Augusta University rabdelsa@augusta.edu	
Case #4	Dr. Kathleen Higgins New York Presbyterian Queens kehiggins22@gmail.com	Dr. Audrey Boros Oral Pathology Associates, Inc. Audrey.boros@gmail.com	
Case #5	Dr. Austin Shackelford Columbia Oral & Maxillofacial Pathology as5629@columbia.edu KAH9156@nyp.org	Dr. Theodora Danciu University of Michigan, School of Dentistry tdanciu@umich.edu	
Case #6	Dr. Rashidah Wiley University of Kentucky College of Dentistry rashidahwiley@gmail.com	Dr. Sonal Shah NYU College of Dentistry sss9@nyu.edu	

2020 AAOMP CPC CASE #1

Nadim Islam BDS, DDS - University of Florida College of Dentistry

CASE STUDY

- 30 y/o Hispanic male with lesion of the right hard palate of 1 month duration. Lesion was associated with pain, swelling and ulceration.



2020 AAOMP CPC CASE #2

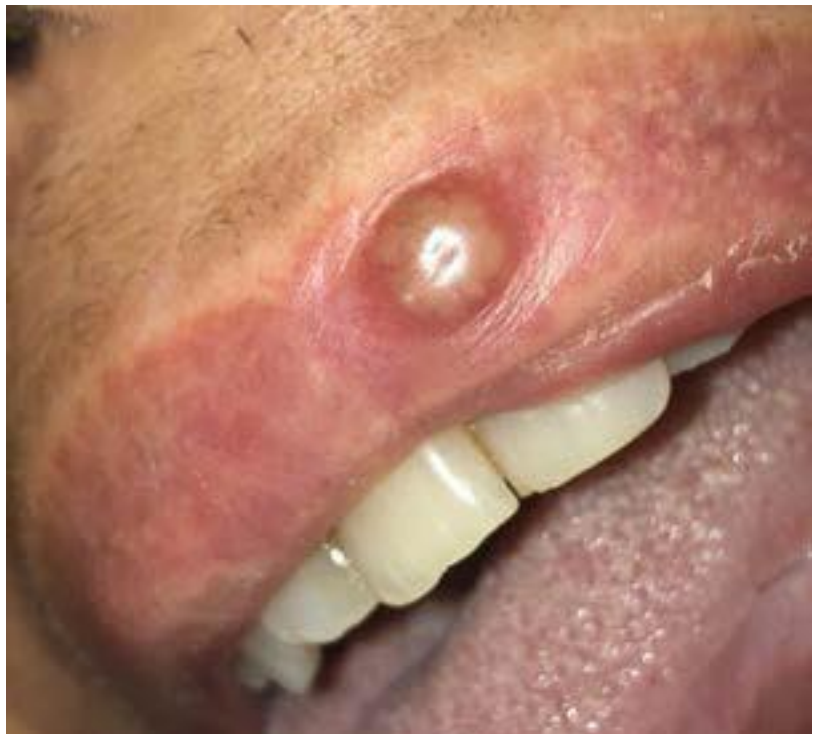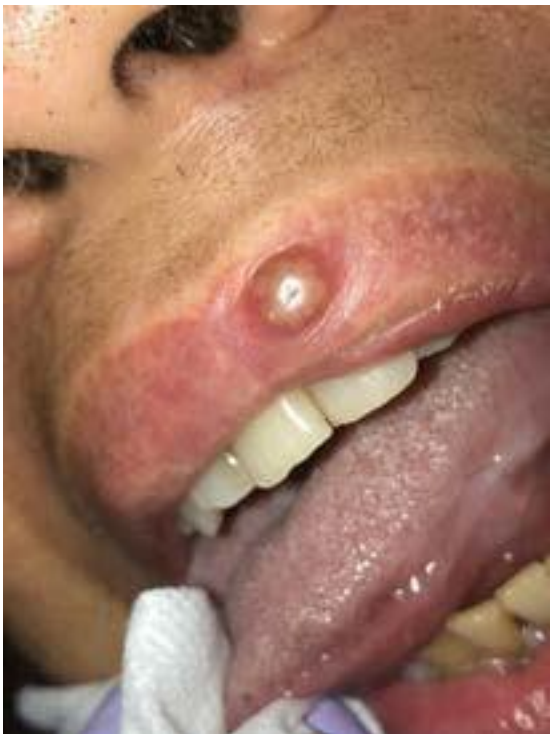Elizabeth Philipone DMD - Columbia University College of Dental Medicine

CASE HISTORY

- 62 y/o F presented to the emergency clinic with a toothache (carious #18). Incidentally, a firm nodule was noted on her upper lip. The lesion is asymptomatic. According to the patient it has been present for several years with little change in size.

MEDICAL HISTORY

- DMII, HTN, hypercholesterolemia, acid reflux, osteoarthritis
- Medications include: aspirin, lisinopril, lipitor, metformin, omeprazole, folic acid, methoxetrate, calcium, naproxen

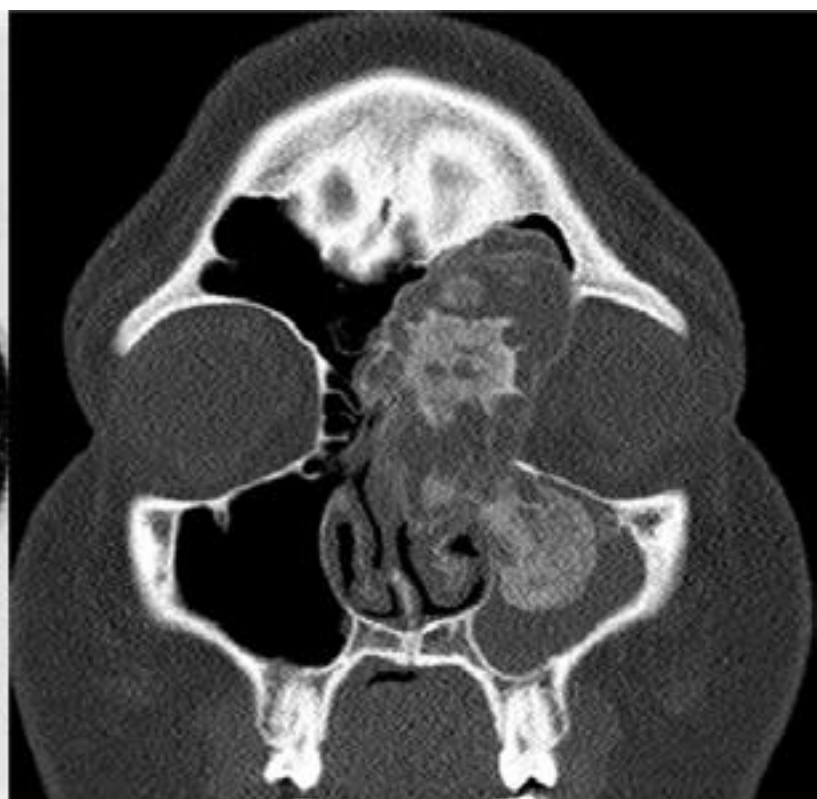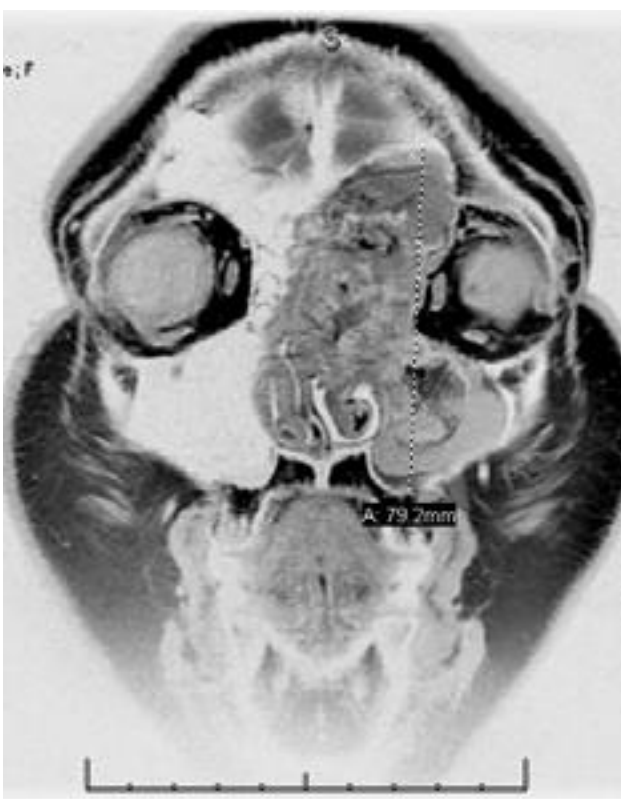


2020 AAOMP CPC CASE #3

Rafik Abdelsayed DDS, MS - The Dental College of Georgia at Augusta College

CASE HISTORY

- 18 y/o female presented with a facial asymmetry and prominent maxillary expansion of unknown duration.

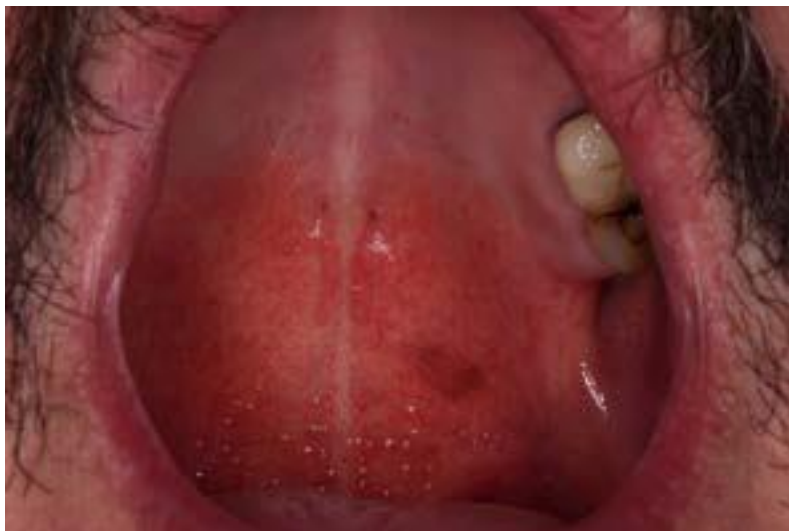
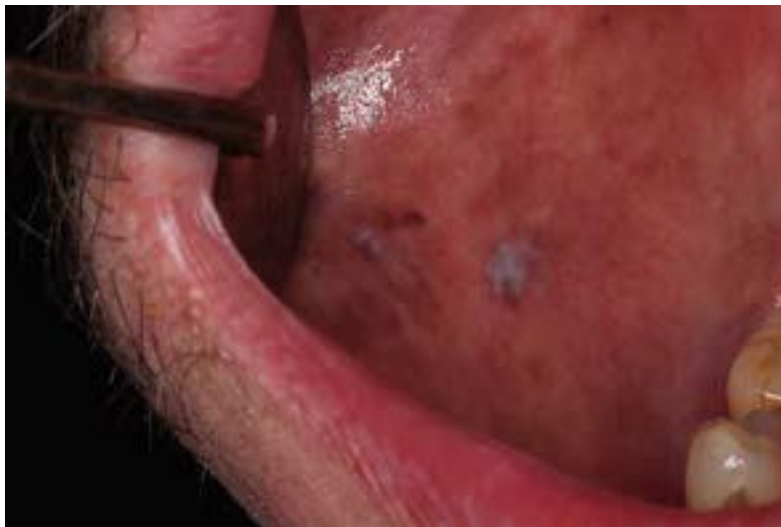
2020 AAOMP CPC CASE #4

Audrey Boros MSc. DDS - Oral Pathology Associates

CASE HISTORY

- 50-year-old male
- Medical history: Non-contributory
- Social history: Significant for heavy smoking of many years duration



2020 AAOMP CPC CASE #5

Theodora Danciu, DMD, DMSc - University of Michigan School of Dentistry

HISTORY of PRESENT ILLNESS

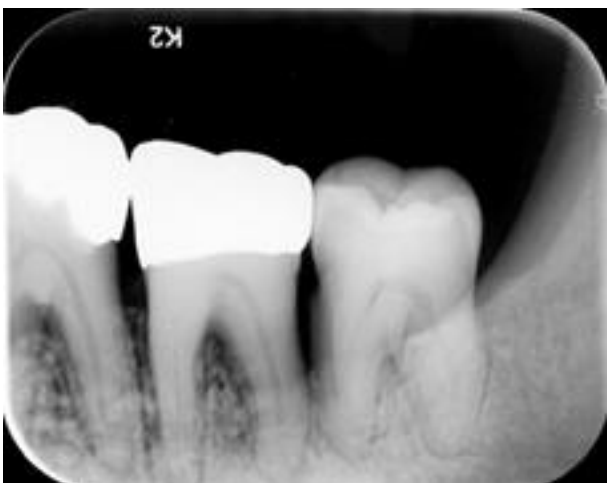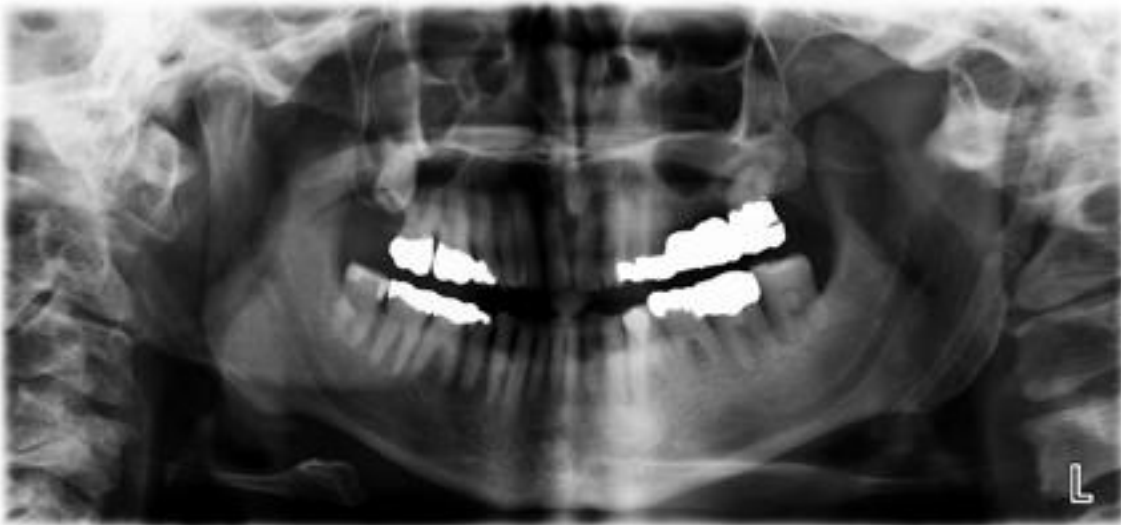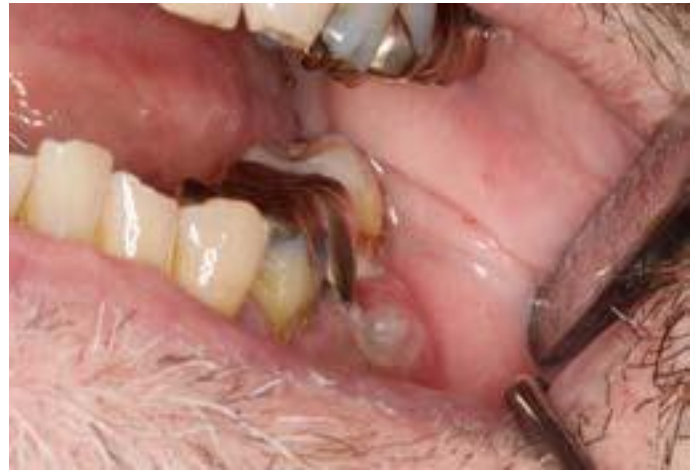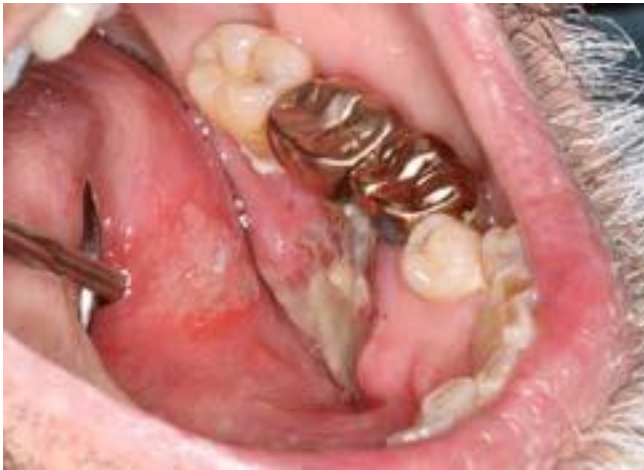- 70 yo Caucasian male
- 6 month history of “raw burn pain” affecting his left posterior mandible

MEDICAL HISTORY

- Primary focal segmental glomerulosclerosis (FSGS)
- Myocardial infarct - 12 years prior
- Total knee arthroplasty due to osteoarthritis - 6 years prior
- Gastroesophageal reflux disease

2020 AAOMP CPC CASE #5

Theodora Danciu, DMD, DMSc - University of Michigan School of Dentistry

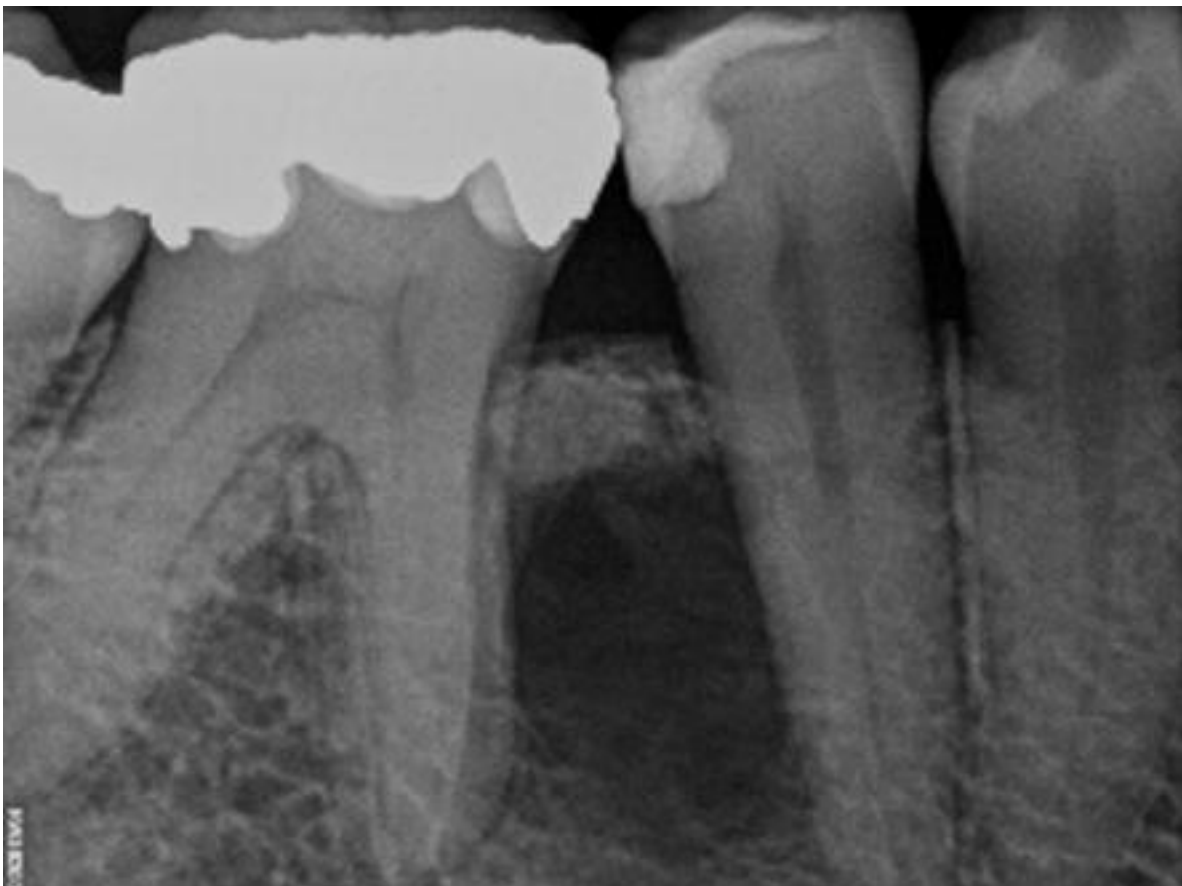

2020 AAOMP CPC CASE #6

Sonal S. Shah DDS, BS - New York University School of Dentistry

CASE HISTORY

- 58 y/o female presented with an asymptomatic mild buccal cortical expansion between teeth #29-30. A periapical x-ray, panorex and CT scan were taken. Upon excision a solid mass was removed.



2020 AAOMP CPC CASE #6

Sonal S. Shah DDS, BS - New York University School of Dentistry

