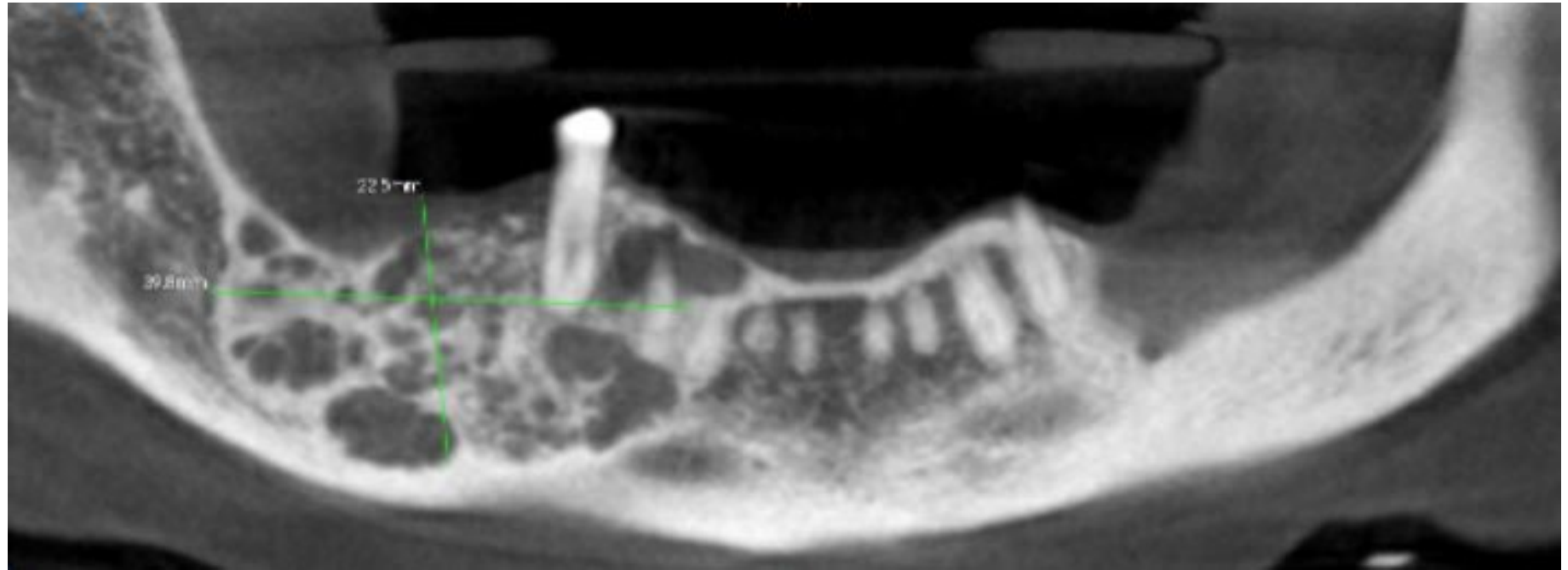


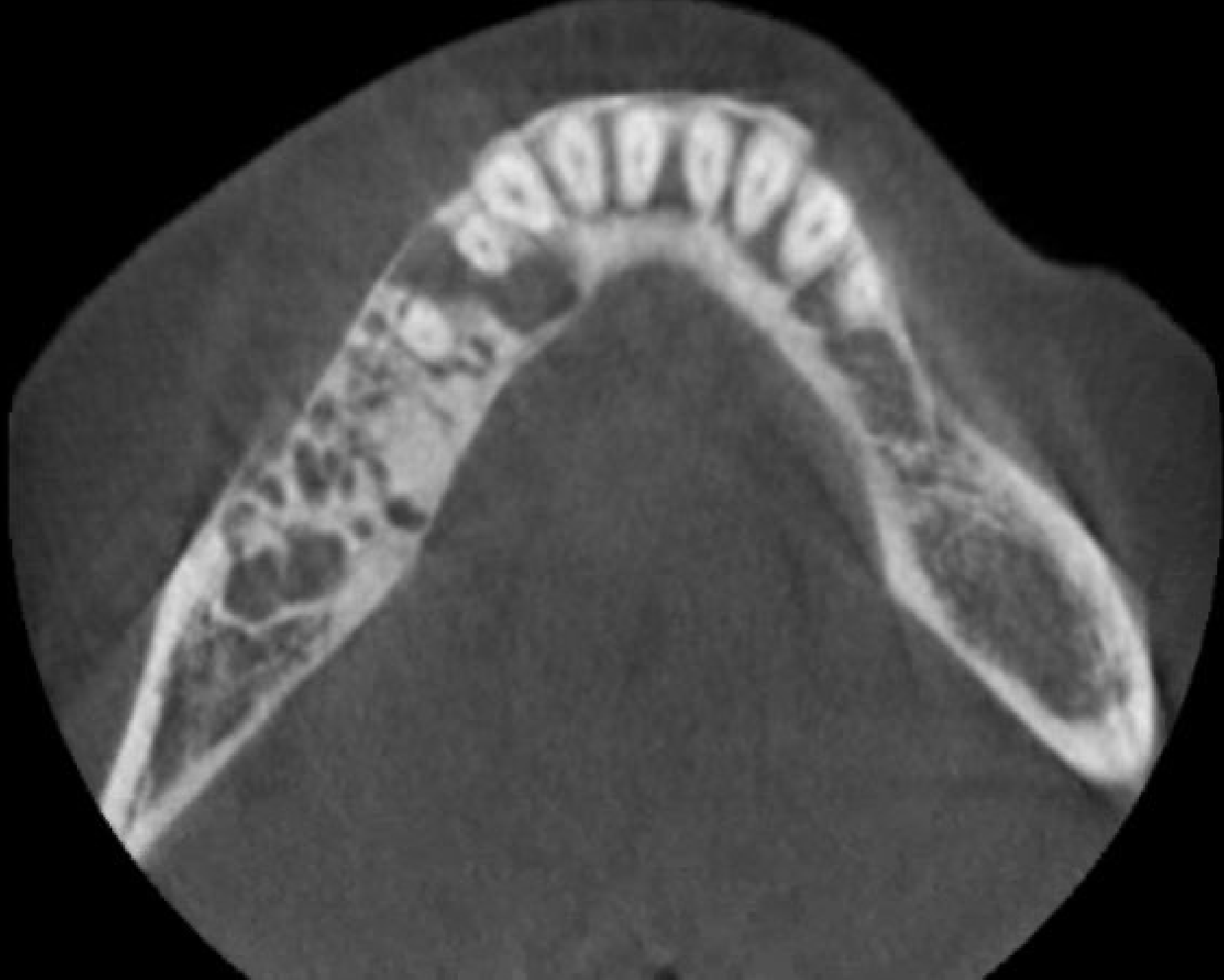AAOMP 2021 CPC CASE # 1

Victoria L. Woo DDS
Texas A&M College of Dentistry

Case History

- 63-year-old female presented to oral surgeon for evaluation of right mandibular lesion
- Recent onset swelling and pain of two months duration
- Extraoral examination revealed mild right-sided facial swelling that was slightly tender to palpation
- On intraoral examination, the mandibular body was expanded and surfaced by normal-appearing mucosa
- Surgical history was significant for a biopsy of the right mandible performed 7 years prior, which was diagnosed as a traumatic (simple) bone cyst





AAOMP 2021 CPC CASE # 2

Mikelle L. Kernig, DDS, MS

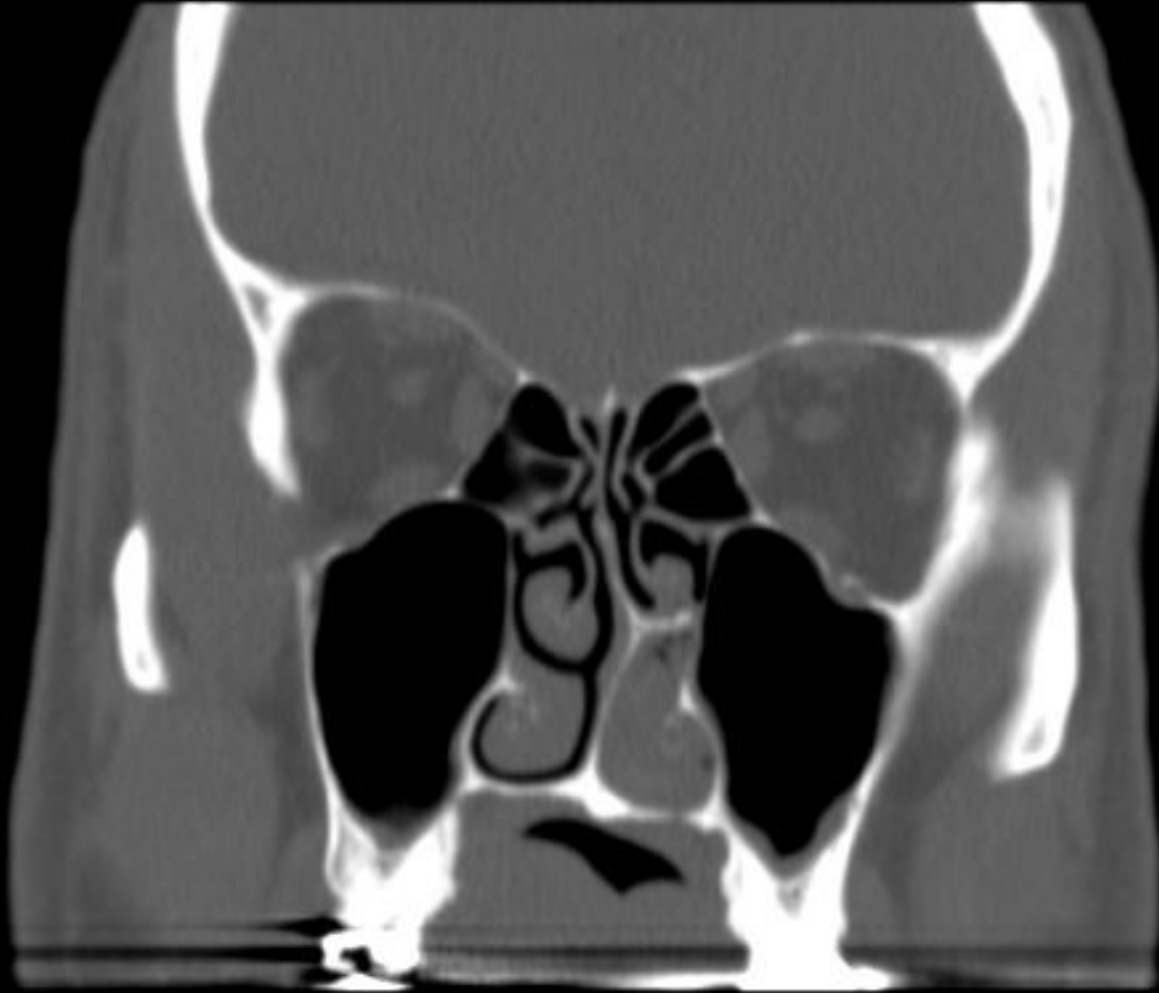
Incyte Diagnostics

Case History

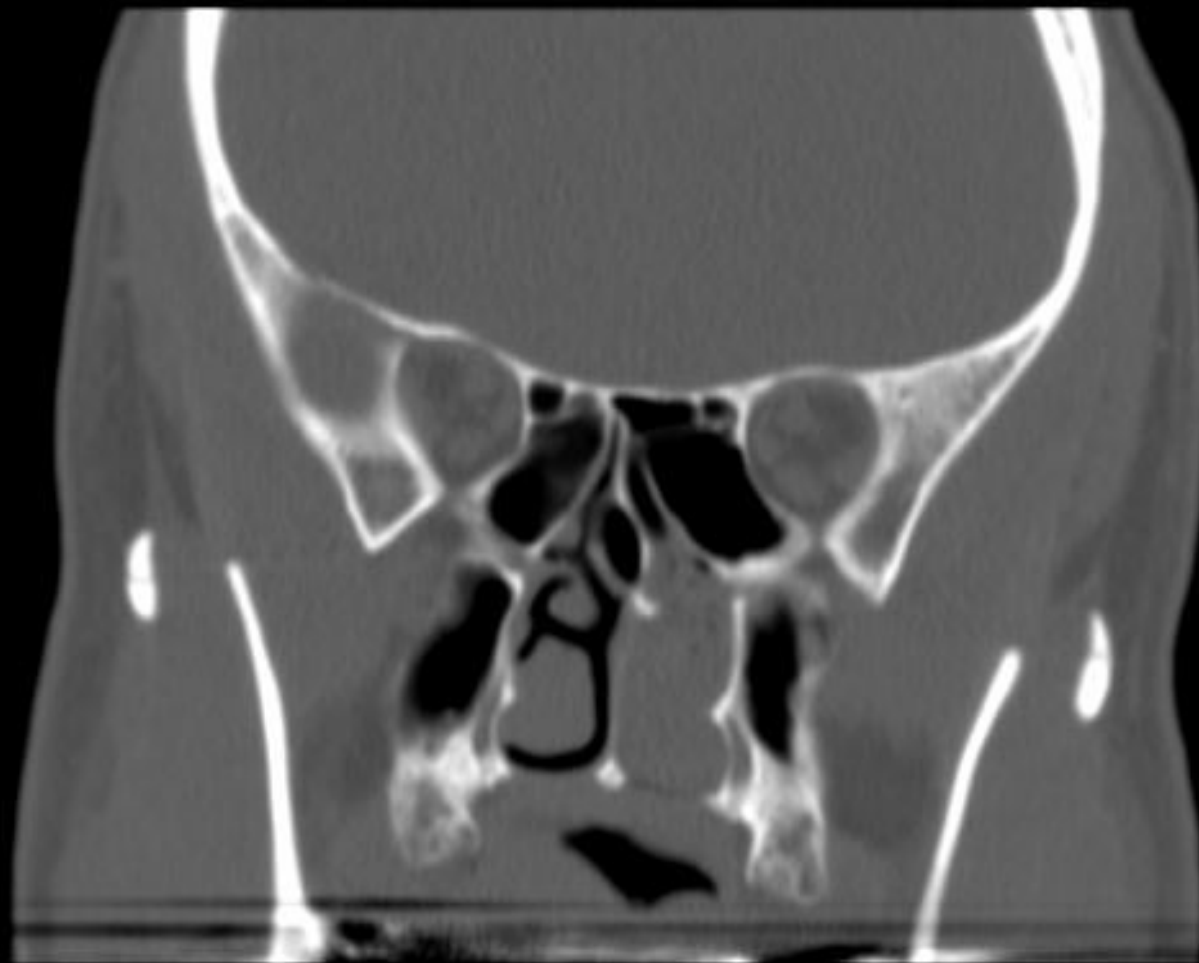- 52-year-old male
- Reports a sense of facial pressure and increased difficulty breathing through nose for past 8 months; occasional headaches
- Imaging reveals a 5.2 cm greatest dimension polypoid mass within the nasopharynx and left posterior nasal cavity
- Scope and clinical eval reveal no other pathology, to include no lymphadenopathy

S78

R
A



S78



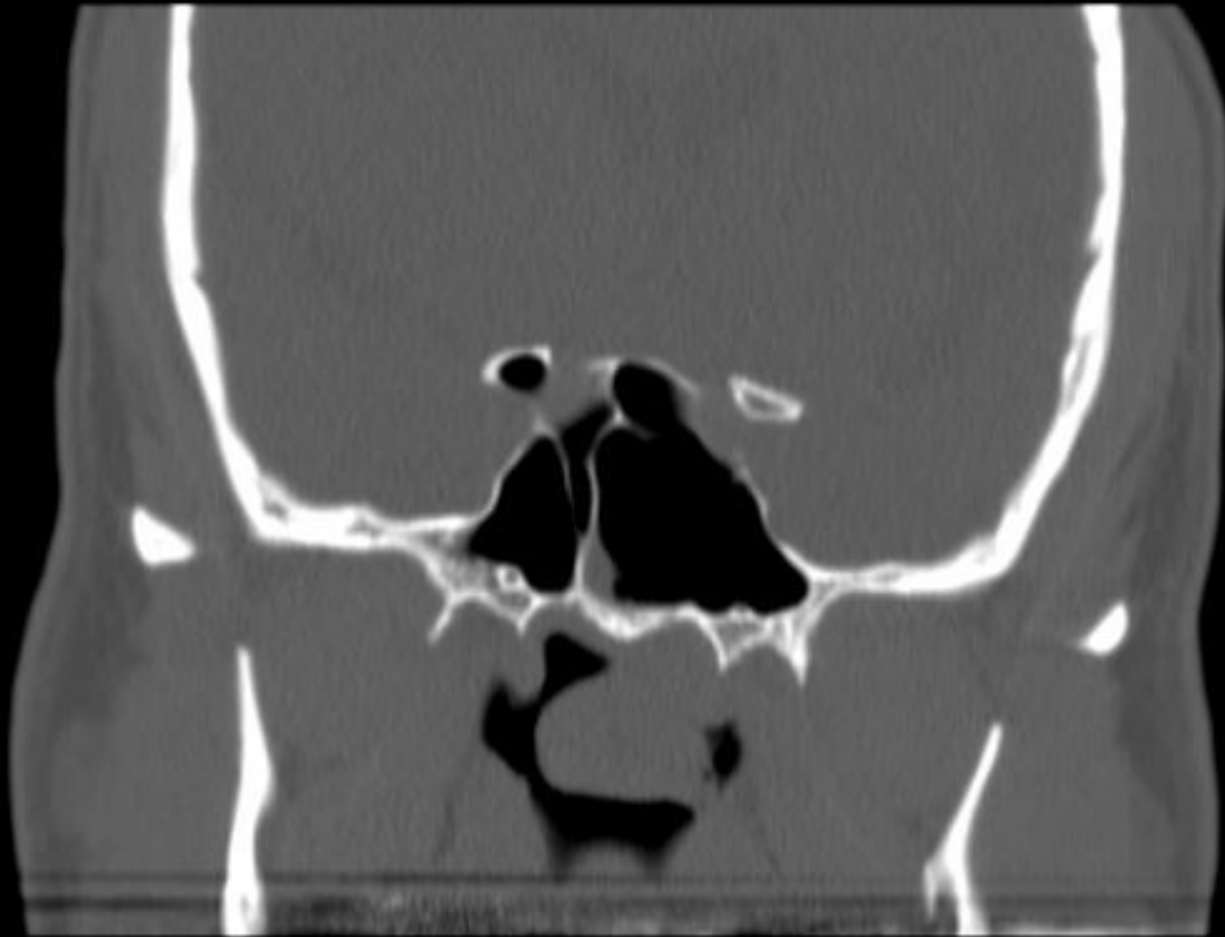
R
A



P
L

S78

R
A



L
P

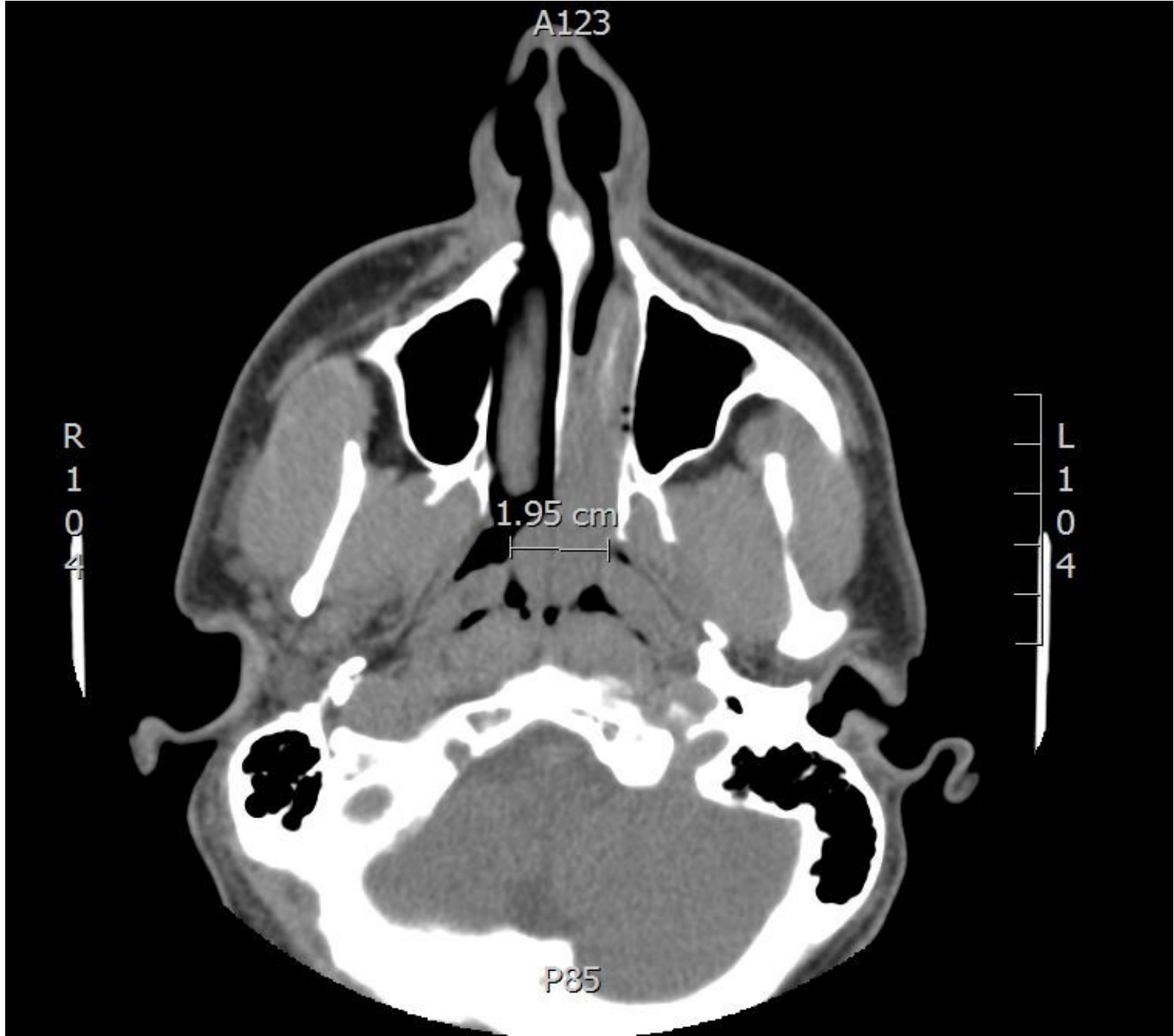A123

R
1
0
4

L
1
0
4

1.95 cm

P85



AAOMP 2021 CPC CASE # 3

Roman Carlos, DDS, MS
Centro Clínico de Cabeza y Cuello

Case History

- 13 y.o. male with aggressive and rapidly growing tumor of the left parotid gland, present for 2 months
- Gross homolateral cervical lymphadenopathy is evident
- Past medical history is unremarkable, and before these lesions the patient had an excellent physical condition
- WBC, Hg, Ht, and urine test within normal limits

Signa 1.5T SYS#GEHCGEHC

SA

MEGAMEDICA

Ex: 6053

Se: 113

Im: 10

DCor: A21,0+C

Mag = 1.2

FL:

ROT:

ET 34

R
N

L
301

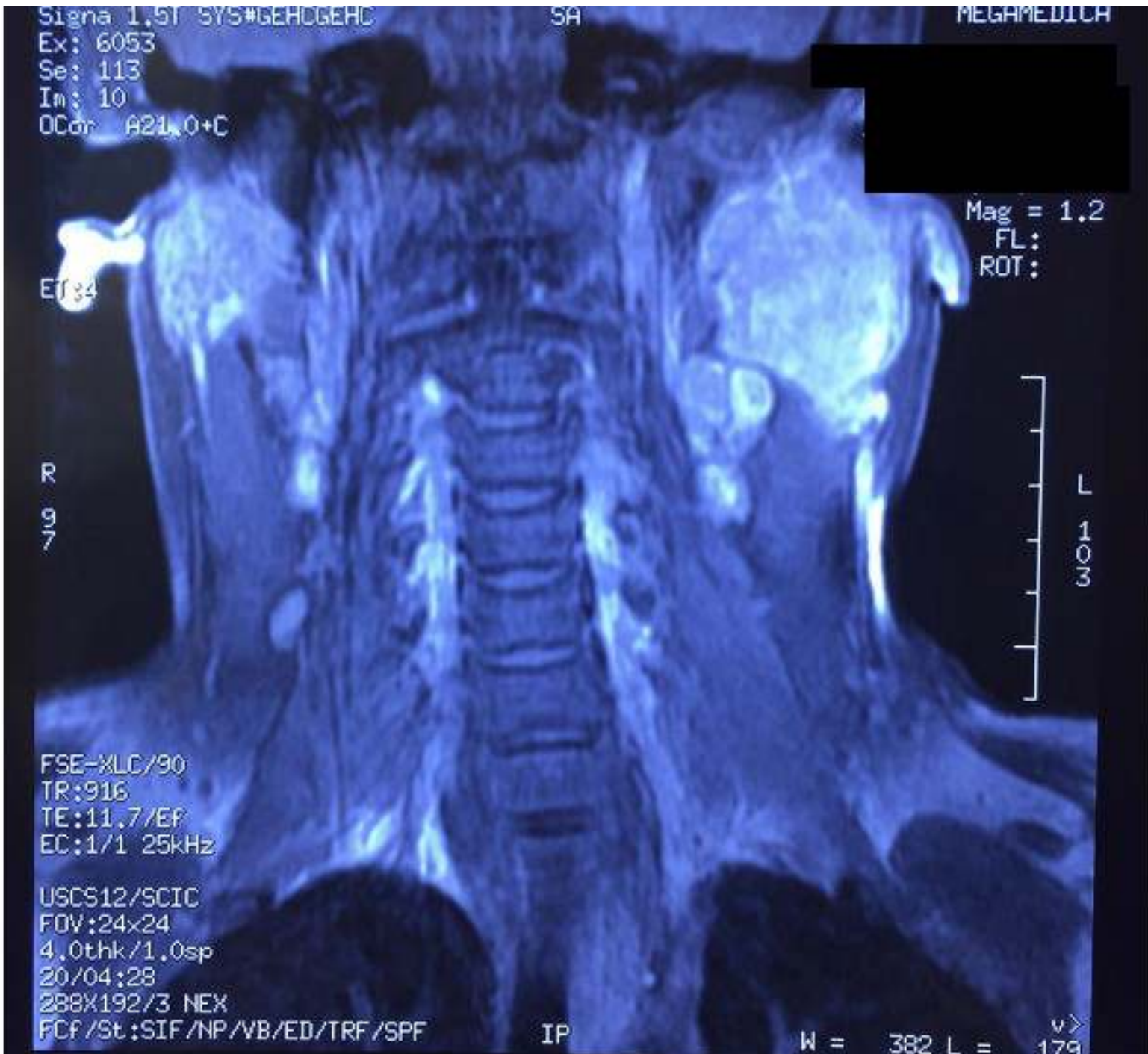FSE-XLC/90
TR:916
TE:11.7/Ef
EC:1/1 25kHz

USCS12/SCIC
FOV:24x24
4.0thk/1.0sp
20/04:28

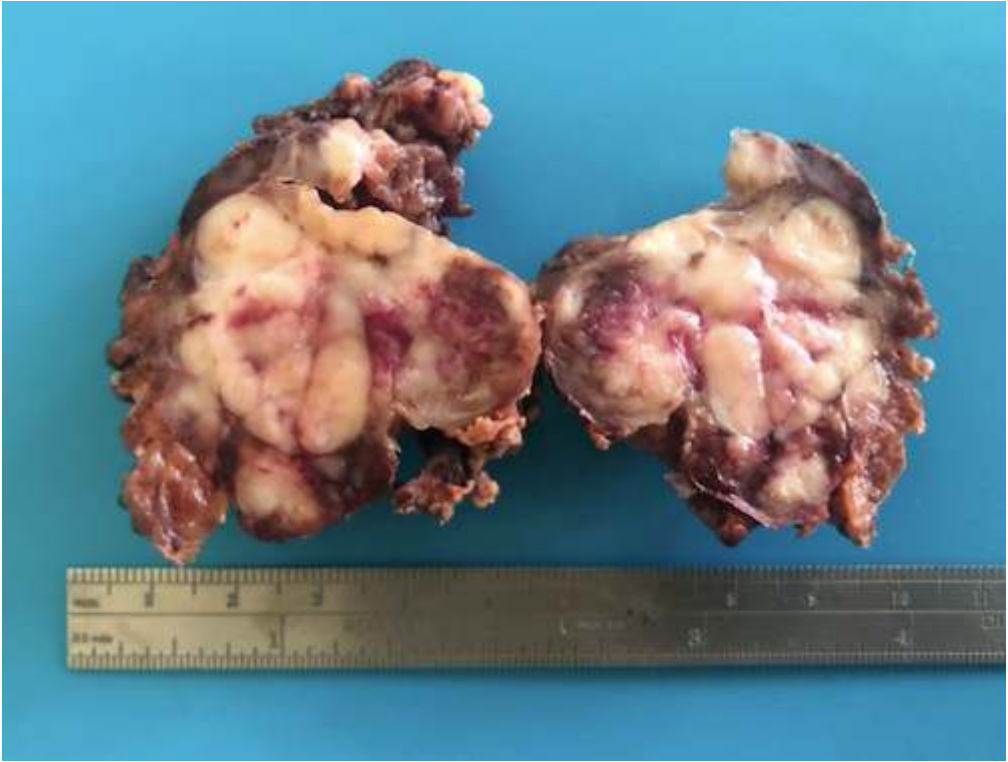
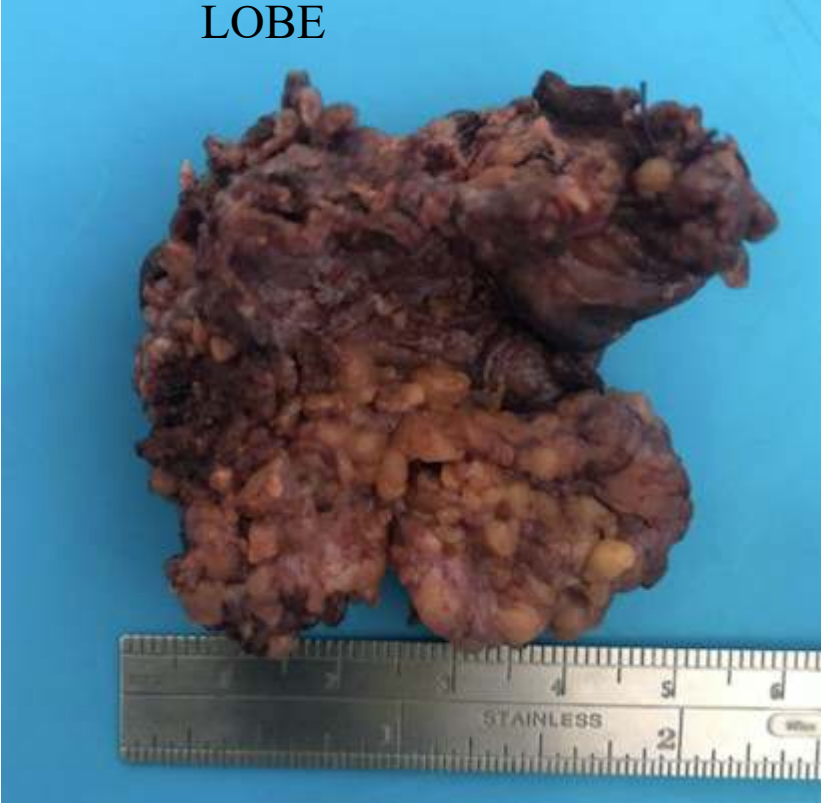288X192/3 NEX
FCF/St: SIF/NP/VB/ED/TRF/SPF

IP

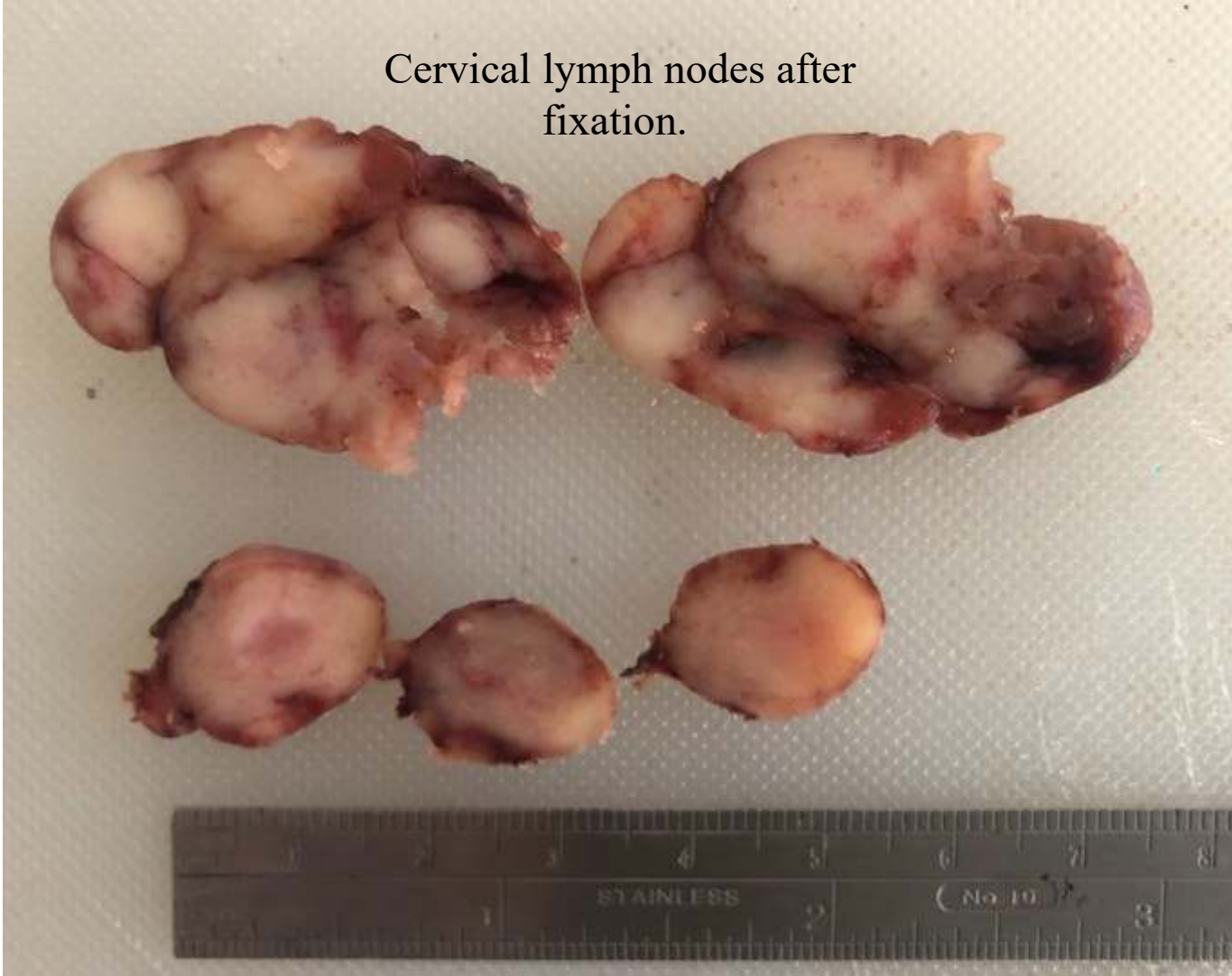W = 382 L = 179



DEEP LEFT PAROTID
LOBE



Cervical lymph nodes after fixation.

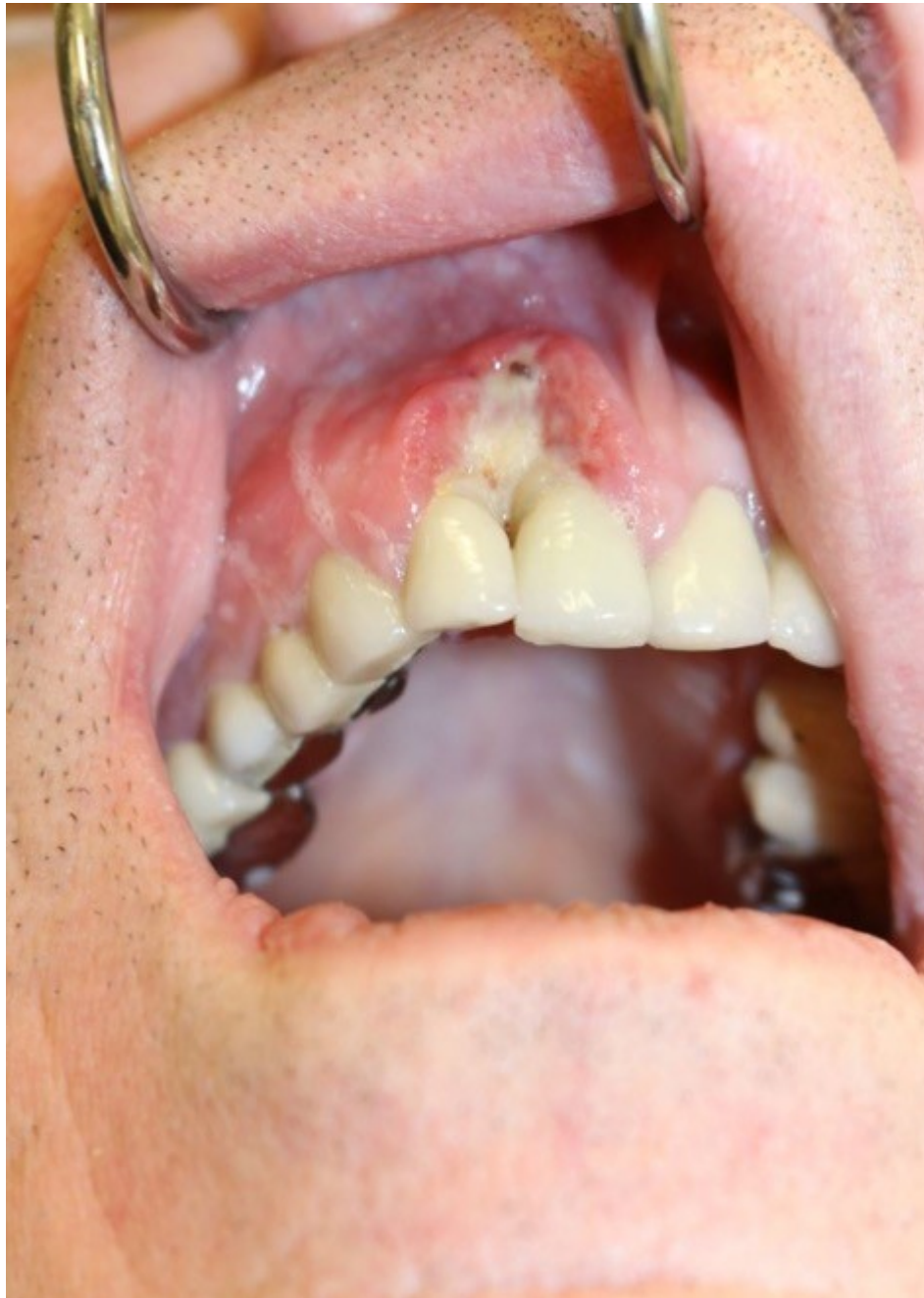

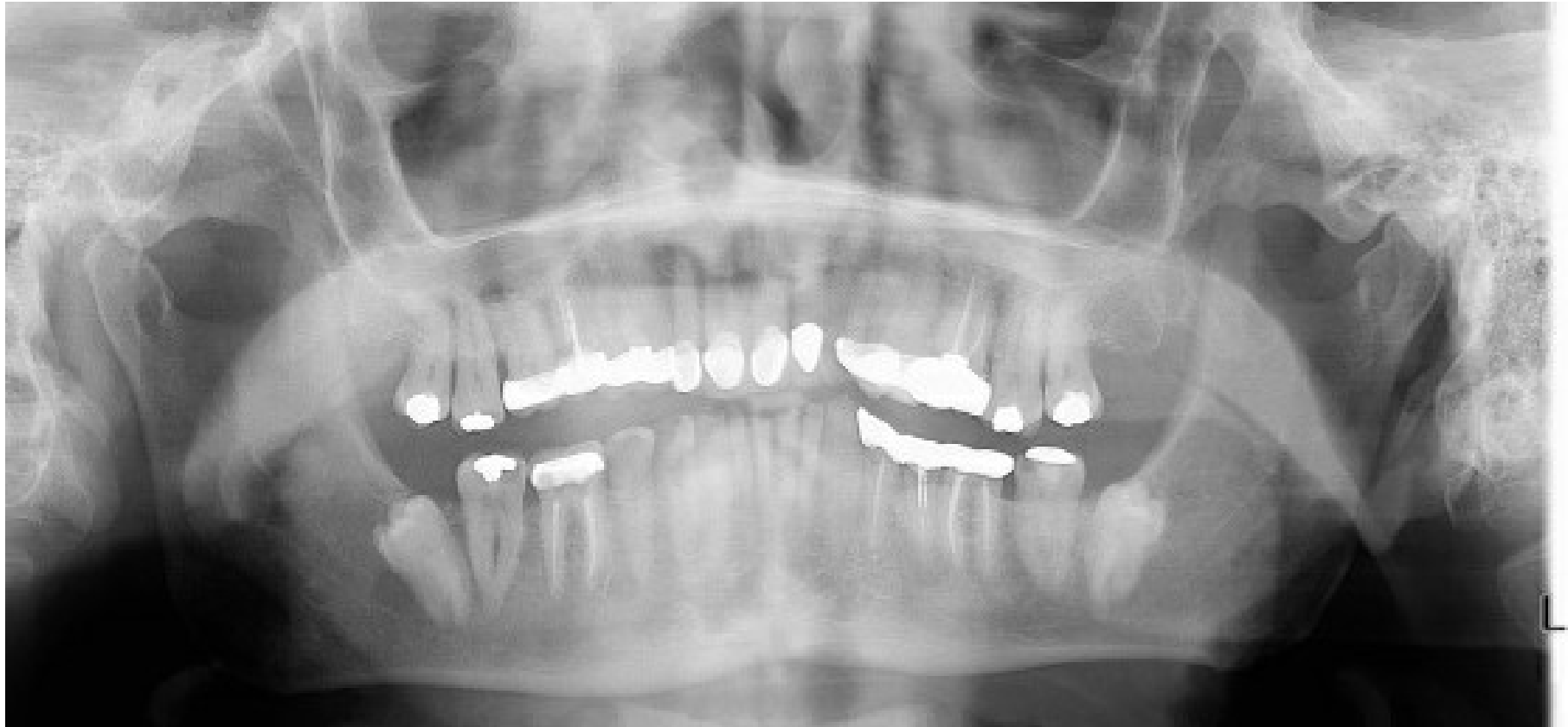AAOMP 2021 CPC CASE # 4

Riya M. Kuklani, DDS
Temple University Hospital

Case History

- 68 year old male
- PMH: Admitted to hospital for abdominal pain and antibiotics were prescribed. Had kidney biopsy with diagnosis of oncocytoma and colon biopsy with diagnosis of ulcerated benign polyp
- Clinical Presentation: 2x2 cm ulcerated erythematous lesion of right maxillary anterior gingiva involving tooth #7 and 8 of unknown duration, denies pain, swelling, drainage or bleeding from the area
- ROS: Negative for cervical lymphadenopathy



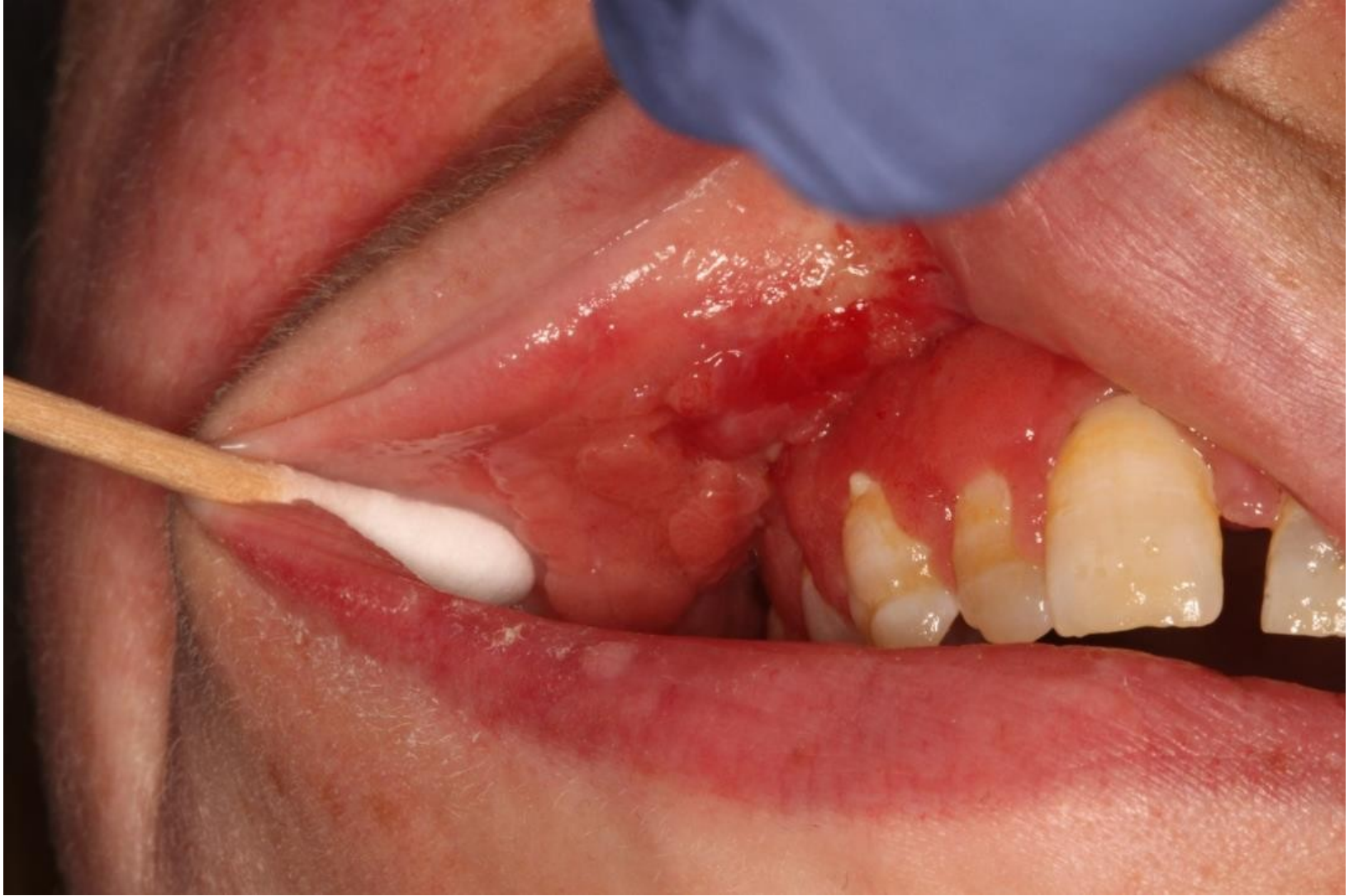


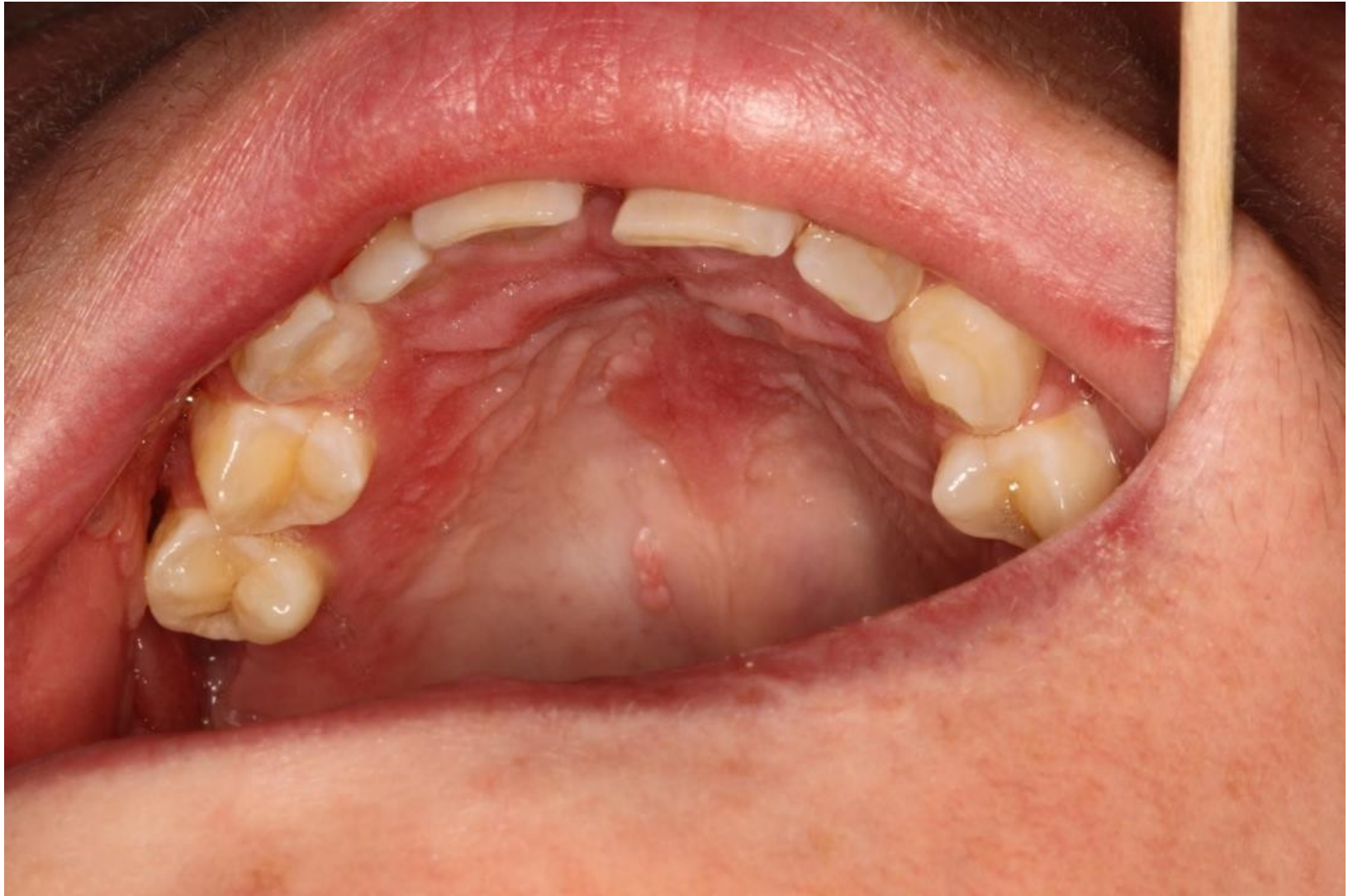AAOMP 2021 CPC CASE # 5

Ricardo J. Padilla , DDS
University of North Carolina
School of Dentistry

Case History

- 28 Caucasian Female
- Bicuspid aortic valve
- Scoliosis
- Delayed and abnormal menses
- Longstanding chronic sinus issues
- Migraines (with light and smell sensitivity)
- Hepatitis B, immunotolerant type, with liver fibrosis on biopsy in 2016 (at age 24). Her father also had it
- Referred for “evaluation of her mouth”
- She is asymptomatic, vital signs within range of normal





AAOMP 2021 CPC CASE # 6

Nasser Said-Al-Naief, DDS, MS
Oregon Health Sciences University
School of Dentistry

Case History

- 52 y.o. female
- PMH: Depression, managed by Paxil
- 6-8 months + history of severe nasal congestion, rhinorrhea and nasal discharge
- Denies epistaxis
- Denies severe pain or paresthesia
- Nonsmoker, only social drinker

